

Fiber-optic bronchoscopy: seven-year experience at Nepal Medical College Teaching Hospital

KC Devkota,¹ R Pathak,¹ A Khanal¹ and R Chokhani²

¹Department of Medicine, Nepal Medical College Teaching Hospital, Attarkhel, Jorpati, Kathmandu, Nepal, ²Norvic International Hospital, Thapathali, Kathmandu, Nepal

Corresponding author: Dr. Ranjan Pathak, Department of Medicine, Nepal Medical College Teaching Hospital, Jorpati, Kathmandu, Nepal; e-mail: findranjanhere@hotmail.com

ABSTRACT

Fiber-optic bronchoscopy is a safe and useful diagnostic and therapeutic tool for the management of the pulmonary diseases. The purpose of this study was to find out the demographic profiles, indications, bronchoscopic findings, and diagnoses of the patients who underwent bronchoscopic examination. Retrospective analysis of 231 consecutive bronchoscopies done in Nepal Medical College Teaching Hospital over the period of seven years (January 2003 to January 2010) was done. The commonest indication was radiological opacity (90.2%), followed by diffuse pulmonary infiltrates (4.3%). Cough was the commonest presenting symptom seen in 89.8% of the patients. 79.7% of the patients were smokers and the history of smoking among the patients diagnosed to have lung cancer was 94%. The commonest bronchoscopic finding was endobronchial growth (47.8%). Histopathological examination revealed malignancy in 53.8% of the patients, of which small cell lung cancer was 22.8% and non small cell lung cancer 77.2%. Even when growth was not visualized on bronchoscopy, biopsies attempted from the segments with radiological abnormality established the diagnosis of malignancy in 10.16%, pulmonary tuberculosis in 5.1% and Sarcoidosis in 2.2% of the cases.

Keywords: Fiber-optic bronchoscopy, pulmonary disease, lung cancer, biopsy

INTRODUCTION

Bronchoscopy has become an increasingly important diagnostic and therapeutic tool for the management of pulmonary diseases. The flexible fiber-optic bronchoscope developed by Ikeda has progressively supplanted rigid bronchoscopy.^{1,2} Fiber-optic bronchoscopy can be easily performed with the patient awake under topical anesthesia, and it offers extensive visualization of the tracheo-bronchial tree. Samples can be collected by several methods like bronchial biopsy, bronchial brushing, aspiration, transbronchial lung biopsy, transbronchial needle aspiration and these combined advantages enhance the diagnostic value of bronchoscopy.³

This retrospective study has been done to share the seven years experience of bronchoscopy at Nepal Medical College Teaching Hospital (NMCTH) and to study the clinical profiles and histopathological diagnoses of the patients who underwent this procedure.

MATERIALS AND METHODS

A retrospective analysis of 231 consecutive fiber-optic bronchoscopies performed at NMCTH from January 2003 to January 2010 was done to find out the demographic and clinical profiles of the patients who underwent. The instrument Pentax EB 1830 video bronchoscope was used for the procedure. A detailed history and thorough clinical examination were carried

out. Contraindications, if any were ruled out. Chest X-rays in both PA and lateral views were obtained in all the patients before the procedure to define the location of the lesion. The patients were kept fasting for at least four hours before the procedure. Premedication with 0.6mg Atropine and 25 mg Promethazine i.m. was administered to all the patients about 30 minutes before the procedure. Lignocaine (4.0%) solution was sprayed in the upper respiratory tract prior to the insertion of the instrument. Supplemental oxygen was administered by the nasal cannula to maintain the oxygen saturation above 90.0% in patients who had low SpO₂ during initial evaluation. The instrument was introduced nasally in majority of the patients. In some patients the instrument had to be introduced orally either because of narrow nasal passages or due to oxygen being administered through the nasal cannula.

RESULTS

This analysis was performed in total of 231 patients who underwent bronchoscopy. Among the 231 cases, the most common indication was radiological opacity, which was seen in 210 patients (90.2%). In 10 patients (4.3%) diffuse pulmonary infiltrate was the indication. Four patients (1.7%) underwent bronchoscopy for hemoptysis with normal chest X ray. In the remaining seven (3.0%) patients, bronchoscopy was done for evaluation of the cause of unexplained, persistent cough (Table-1).

Table-1: Indication for bronchoscopy

Indication	n	%
Radiological opacity	210	90.2%
Diffuse pulmonary infiltrates	10	4.3%
Hemoptysis with normal Chest X ray	4	1.7%
others	7	3.0%

Table-2: Clinical features

Clinical features	n	%
Cough	203	89.8%
Hemoptysis	100	44.2%
Shortness of breath	154	68.1%
Wheeze	56	24.8%
Chest pain	128	56.6%
Fever	74	32.7%

Of the 231 patients evaluated 151 (65.4%) were males and 80 (34.6%) patients were females (Fig. 1).

Most of the patients were above 50 years of age (Fig. 2). The youngest patient who had undergone bronchoscopy was 15 years old.

Cough was the most common presenting symptom in 20 (89.8%) of the patients. Shortness of breath, chest pain, hemoptysis were present in 154 (68.1%), 128 (56.6%) and 100 (44.2%) patients respectively. Wheezing was present in 56 (24.8%) patients (Table-2).

One hundred eighty four (79.7%) patients were smokers (present or past) and 47 (20.3%) patients were non- smokers.

The commonest finding on bronchoscopy was endobronchial growth, seen in 108 (47.8%) patients.

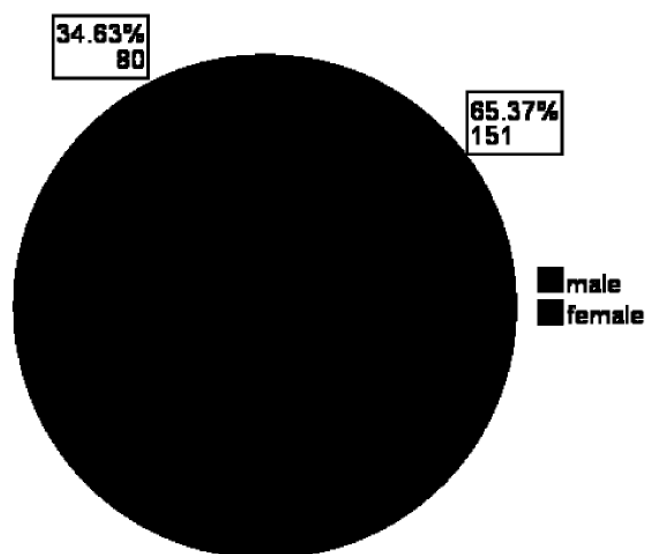


Fig. 1. Sex distribution

Table-3: Bronchoscopic findings

Bronchoscopic diagnoses	n	%
Endobronchial growth	108	47.8%
Suspected growth	9	4.0%
Non specific Inflammation	23	10.2%
Inconclusive	59	26.1%
Normal	32	11.9%

Endobronchial abnormality without obvious growth was seen in nine patients (4.0 %). 23 (10.2%) patients had non specific inflammatory changes. bronchoscopy was inconclusive in 59 (26.1%) patients whereas in 32 (11.9%) patients bronchoscopy was normal (Table-3).

Pathological examination of the specimen obtained by bronchoscopy was performed.

On cytology, malignancy was seen in 40 (19.5%) patients, suspicious malignancy in 25 (12.2%) patients and inflammation in 17 (8.3%) patients. The cytology was normal in 123 patients (60.0%) (Table-4).

On histopathological examination of the 171 cases, malignancy was found in 92 (53.8%). non-specific inflammation in 26 patients (15.2%), pneumoconiosis in 12 (7.0%) and tuberculosis in seven (4.1%), Sarcoidosis in 2 (1.2%), normal in 18 (10.5%) and inconclusive in 14 (8.2%) cases (Table-5).

DISCUSSION

Of the total cases that had undergone bronchoscopy, the majority were males (65.4%), and most of the patients were from the age group of 60 to 70 years. There was a gradual increase in the number of patients requiring bronchoscopic examination till the age group of 60 to 70. Among the age group 60 to 70, 37 (50%) of the patients had bronchogenic carcinoma. This may be due

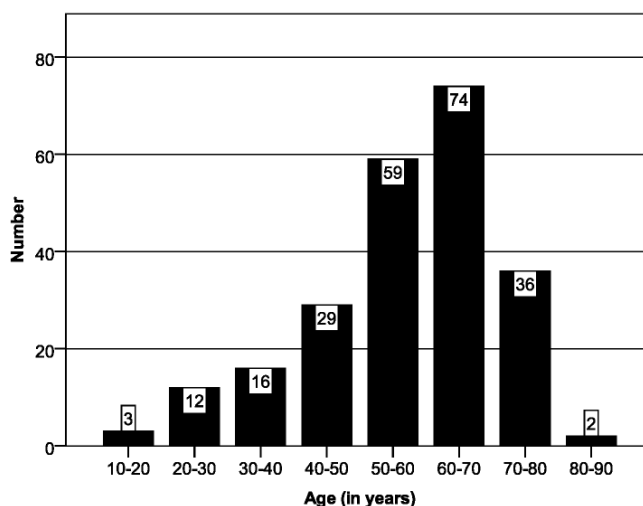


Fig. 2. Age distribution

Table-4: Cytological diagnoses

Cytological diagnoses	nr	%
Confirmed malignancy	40	19.5%
Suspected malignancy	25	12.2%
No malignancy	123	60.0%
Inflammation	17	8.3%

to the higher incidence of bronchogenic carcinoma with increasing age.

Cough was the commonest indication (89.8%) for bronchoscopy, which is similar to a previously published study.² A change in the character of the 'regular' cough of a smoker or a COPD patient, particularly if it is associated with other new respiratory symptoms, the possibility of bronchogenic carcinoma should be ruled out. COPD and bronchogenic carcinoma share similar etiology like smoking, so COPD and bronchogenic carcinoma often coexist. Epidemiological studies suggest majority of patients with bronchogenic carcinoma have signs and symptoms of COPD.^{4,5}

The most important indications for bronchoscopy in this study were opacity on chest X ray, pleural effusion and hemoptysis. Bronchogenic carcinoma was the commonest cause of hemoptysis in our study. This is similar to other published studies.⁶⁻⁸

The most common finding at bronchoscopy was endobronchial growth, seen in 108 (47.8%) of cases. Out of 59 patients with inconclusive bronchoscopy, histopathological examination of attempted biopsy (45 cases) revealed malignancy in six (10.16%), pulmonary tuberculosis in three (5.1%), sarcoidosis in one patient (2.2%). Bronchogenic carcinoma was the commonest disease which was diagnosed by histopathological examination in 92 (53.8%) patients. In another study done in a tertiary care hospital in Kathmandu, lung cancer was diagnosed in similar percentage.⁹

Of all the bronchogenic carcinoma diagnosed, 71 (77.2%) had non-small cell carcinoma and the rest of

Table-5: Histological diagnoses

Histological diagnoses	n	%
Inconclusive	14	8.2%
Normal	18	10.5%
Malignancy	92	53.8%
Tuberculosis	7	4.1%
Pneumoconiosis	12	7.0%
Non-specific inflammation	26	15.2%
Sarcoidosis	2	1.2%

the patients 21 (22.8%) had small cell carcinoma. This finding is similar with other published series.¹⁰

It has been established that smoking is the most important risk factor for the causation of lung cancer.¹¹⁻¹⁴ The cumulative lung cancer risk among heavy smokers may be as high as 30 percent, compared with a lifetime risk of lung cancer of 1 percent or less in nonsmokers.^{15,16} Smoking is associated with more than 90.0% of lung cancers.¹⁷ Similarly, in our study, majority (92.4%) of the cancer patients were smokers.

We used the combination of various procedures like biopsy, aspirate, and brush smear for diagnostic evaluation. All these procedures should be attempted during bronchoscopic examination to increase the diagnostic yield.^{18,19} Sometimes, aspirate and brush smear cytology can still establish the diagnosis even when biopsy is negative in the same case.

Various complications have been reported with bronchoscopy. In a retrospective study of more than 4,000 flexible bronchoscopies, the frequency of complications was 1.3 percent.²⁰ Approximately 25 percent of all complications can be attributed to premedications or anesthetic drugs.²¹ In our study not a single patient suffered from any major complications. Mild to moderate hemorrhages was noticed in some cases during the procedure which were self-limiting.

Our study covers only the diagnostic use of bronchoscopy. Because of lack of other accessories and sophisticated instruments for therapeutic interventions, fiber-optic bronchoscopy has been limited to diagnostic purposes in our set up.

Bronchoscopy is a safe and useful tool for making the diagnosis of a variety of pulmonary diseases like bronchogenic carcinoma, pulmonary tuberculosis and some interstitial lung diseases. In our study Cough and hemoptysis were the commonest presenting symptoms of the patients. Radiological opacity was the commonest indication. Endobronchial growth and malignancy were the commonest findings on bronchoscopy and histopathological examination respectively. Moreover, we would like to emphasize the importance of attempting biopsy from the abnormal segment of the lung even when bronchoscopy does not show frank mucosal growth.

REFERENCES

- Zollner F. Gustav Killian-Father of bronchoscopy. *Arch otolaryngol* 1965; 82: 656.
- Prakash UBS, Offord KP, Stubbs SE. Bronchoscopy in North America: The ACCP survey. *Chest* 1991; 100: 1668-75.
- Willcox PA, Benatar SR, Potgieter PD *et al.* Fibre-optic bronchoscopy Experience at Groote Schuur Hospital. *SA Med J* 1981; 20: 651-4.

4. Cohen BH, Diamond EL, Graves CG *et al*. A common familial component in lung cancer and chronic obstructive pulmonary disease. *Lancet* 1977; 2: 523-36.
5. Abal Arca J, Parente I, Almazán RL. Lung cancer and COPD: a common combination. *Arch Bronconeumol* 2009; 45: 502-7.
6. Johnston H, Reisz G. Changing spectrum of hemoptysis. Underlying causes in 148 patients undergoing diagnostic flexible fiberoptic bronchoscopy. *Arch Intern Med* 1989; 149: 1666-8.
7. Santiago S, Tobias J, Williams AJ. A reappraisal of the causes of hemoptysis. *Arch Intern Med* 1991; 151: 2449-51.
8. Hirshberg B, Biran I, Glazer M, Kramer MR. Hemoptysis: etiology, evaluation, and outcome in a tertiary referral hospital. *Chest* 1997; 112: 440-4.
9. Chokhani R. Lung cancer diagnosis by bronchofiberoscopy in a chest clinic in Kathmandu. *Nepal Med Coll J* 1998; 1: 25.
10. Wahbah M. Changing trends in the distribution of the histologic types of lung cancer: a review of 4,439 cases. *Ann Diagn Pathol* 2007; 11: 89.
11. Alberg AJ, Samet JM. Epidemiology of lung cancer. *Chest* 2003; 123 (1 Suppl): 21S-49S.
12. Report of the Surgeon General. The Health Consequences of Smoking: Cancer. DHHS (PHS) 82-50179. Washington, US Department of Health and Human Services, 1982.
13. U.S. Department of Health, Education, and Welfare. Smoking and Health: Report of the Advisory Committee to the Surgeon General of the Public Health Service. Washington: U.S. Department of Health, Education, and Welfare, Public Health Service, Center for Disease Control, 1964. PHS Publication No. 1103.
14. The Health Consequences of Smoking: A Report of the Surgeon General. U.S. Department of Health and Human Services, Public Health Service, Centers for Disease Control and Prevention, Washington, DC 2004. CDC Publication No. 7829.
15. Samet JM. Health benefits of smoking cessation. *Clin Chest Med* 1991 Dec; 12(4):669-79.
16. Samet JM, Wiggins CL, Humble CG, Pathak DR. Cigarette smoking and lung cancer in New Mexico. *Amer Rev Respir Dis* 1988 May; 137(5): 1110-3
17. Bach P, Ginsberg RJ. Epidemiology of lung cancer. In Ginsberg RJ, editor. Lung cancer. Hamilton: BC Decker, 2002: 1-10.
18. Wallace MB, Pascual JM, Raimondo M *et al*. Minimally invasive endoscopic staging of suspected lung cancer. *J Amer Med Assoc* 2008; 299: 540-6.
19. Chokhani R, Udas PB, Devkota KC, Dhungel S. Clinical and Histo-cytological profile of 200 consecutive video Bronchoscopies Experience at NMCTH. *Nepal Med Coll J* 2002; 4: 64-67.
20. Pue CA, Pacht ER. Complications of fiberoptic bronchoscopy at a university hospital. *Chest* 1995; 107: 430-2.
21. Credle WF, Smiddy JF, Elliott RC. Complications of fiberoptic bronchoscopy. *Amer Rev Respir Dis* 1974; 109: 67.