

Management of urethral strictures and their outcome

RK Chhetri¹, GK Shrestha², HN Joshi³ and RKM Shrestha⁴

^{1,3,4}Department of Surgery, Dhulikhel Teaching Hospital, Dhulikhel and ²TU Teaching Hospital, Maharajgunj, Kathmandu, Nepal

Corresponding author: Dr. Guna Kumar Shrestha, MD, Associate Professor, Department of surgery, Urology Unit, TU Teaching Hospital, Maharajgunj, Kathmandu, Nepal P.Box No: 3578, e-mail: tuthsurgery@gmail.com, tuthsurgery@yahoo.com

ABSTRACT

Urethral stricture is a challenging surgical problem since the ancient time. Its outcome is very poor because of the high recurrence rate 40.0-50.0% whatever procedure is conducted to treat the condition. Between January 2004 to December 2007, 61 cases with urethral stricture were treated in our hospital. Management of stricture was decided according to the grading of urethral stricture. Of 61 cases, 42 (68.8%) had grade I-II, 10 (16.4%) had grade III and 9 (14.8%) had grade IV strictures. They were treated with optical internal urethrotomy (OIU), modified railroading and end to end anastomotic urethroplasty respective to gradings. During the average 2 years follow up period, outcome of strictures were analyzed. Recurrence of stricture was noted 31.0% in grade I-II after OIU and 11.0% in grade IV after urethroplasty. However, in cases with grade III stricture recurrence rate was observed in 60.0% after modified railroading. During the follow up period, 50.0% of the grade III strictures were converted to urethroplasty. It is suggested that, OIU is still a gold standard procedure to manage the lower grade (I-II) strictures with low morbidity, minimally invasive and success rate is 69.0%. End to end anastomotic urethroplasty for grade IV stricture has very good result (89.0%) but needs skilful mobilization of distal urethra to prevent chordee. However, grade III stricture needs open urethroplasty or modified railroading by using flexible cystoscopy which may reduce recurrence rate.

Keywords: Anastomotic urethroplasty, modified railroading, optical internal urethrotomy.

INTRODUCTION

Urethral stricture remains complicated surgical problem for mankind since ancient time and thus the treatment remains to evolve. In the history, the earliest recorded attempt to treat the stricture was metal dilator which was described in Ayurveda in 16th century.¹ Later on it was replaced by blind internal urethrotome by Civiale and Otitis in 18th century but had not gained much popularity because of their complications and poor result. After the introduction of endoscopic optical system by Hopkins 1960 and later Sachse 1970 much improvement was found in recurrence rate.²

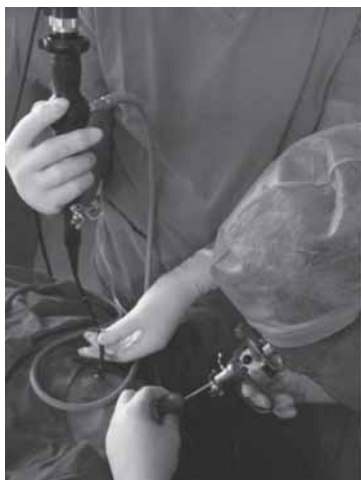

Fig. 1. Modified railroading' by 'Flexible Cystoscopy' for Grade III stricture.

Urethral stricture is still unsolved problem because of its recurrence (40.0-50.0%). The corpus spongiosum which encircle the anterior urethra leads to extensive fibrosis (corpus spongiosum fibrosis) after a trivial injury and cause recurrent stricture.³ Dilatation, Optical Internal Urethrotomy (OIU) by cold knife and urethroplasty are the modalities used to restore the continuity of the urethra. However, none of the modalities are satisfactory to manage the urethral stricture because of the reformation of fibrosis and stricture. In this study we are trying to find out suitable modalities of treatment according to the grading of stricture which help to plan the management and may reduce the recurrence rate.

MATERIALS AND METHODS

This is a prospective analytical study conducted in the Kathmandu University Dhulikhel Hospital, Department of Surgery Urology Unit from January 2004 to December 2007 (four years). All male with urethral injuries and stricture irrespective to age and cause were enrolled in this study. The mean age was 36.2 years (ranging from 10–70 years). Diagnosis of urethral injury at the casualty department was made with history of fall injury or trauma or road traffic accident followed by retention of urine, blood in the urethral meatus or hematuria and boggy swelling with ecchymosis around the scrotum or perineum. Patients with complete urethral injury and

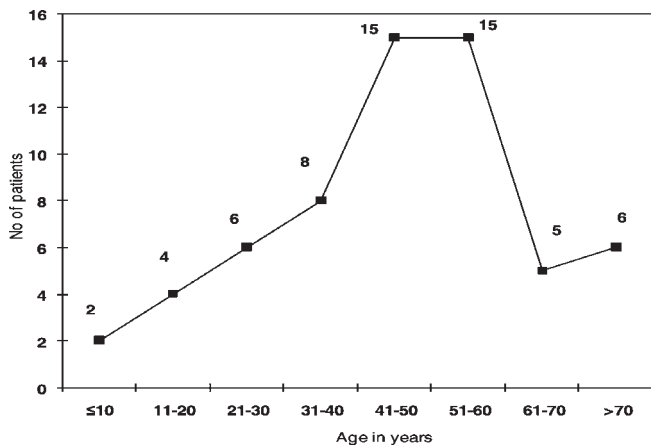


Fig. 2. Age distribution of urethral stricture

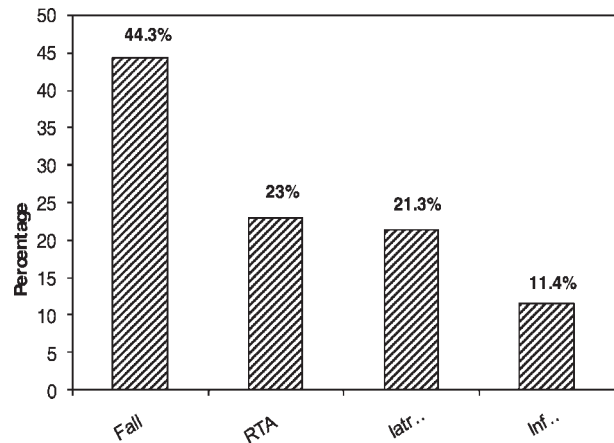


Fig. 3. Etiology of urethral stricture

retention of urine were managed by suprapubic catheter (SPC) at the casualty department after the restoration of vital status.

Confirmation of urethral injury was made by retro/antegrade urethrocytogram (UCG) contrast study. X-ray KUB or pelvis and Ultrasonography (USG) abdomen were routinely performed to rule out other associated visceral or bone injuries. Grading of urethral strictures were made according to Jordan⁴ and it is modified with ante and retro grade UCG findings (Table-1).

Management of urethral strictures were proceeded after 3-6 weeks of primary injury and it was decided according to the grading of urethral stricture. Lower grade urethral stricture (grade I and II) were subjected to OIU and grade III stricture with suprapubic catheter was subjected to modified railroading (Antegrade Sound Assisted OIU)⁵ by using metallic bougie or flexible cystoscopy antegradely through suprapubic port and OIU is

performed retrogradely by Sachse urethrotome (Fig. 1). Grade IV urethral stricture were subjected to end to end anastomotic urethroplasty after excision of fibrous tissue and mobilization of distal urethra. After the procedure patients were discharged from hospital 1-7 days according to the type of surgery. Follow up were carried out after 7-14 days according to the type of procedure conducted.

During the follow up as required, we carried out urethral dilatation or clean intermittent self catheterization (CISC) or cystoscopy evaluation or residual OIU according to the need. We advised patient to come every week or fortnight for 6 weeks, then every month for 6 months and every year for 6 years.

RESULTS

The most common age group for stricture were 40-50 yrs (Fig. 2) and cause of stricture was found to be trauma, of which fall injury were 44.3% followed by road traffic

accident and iatrogenic (Fig. 3). The common site of stricture was noted at bulbous in anterior and membranous in posterior urethra. According to the grading of urethral stricture grade I comprised of 44.3%, grade II, III and IV were 24.6%, 16.4% and 14.7% respectively (Fig. 4).

Outcome of the urethral strictures were observed after the removal of catheter during the follow up period. In grade I and II strictures after OIU, satisfied voiding were noted in 69.0% and 89.0% in grade IV strictures after end to end anastomotic urethroplasty. However, in patients with grade III stricture, modified railroading

Table-1: Modified grading of urethral stricture incorporated with UCG findings

Grades	Description of stricture, Jordan 1987	Pathological findings	UCG findings
I	Pinhole stricture (<5mm) only urethral mucosa is involved		
II	Incomplete urethral stricture (<10mm) with partial corpus spongiosus fibrosis		
III	Complete urethra stricture (1-2cm) with full thickness corpus spongiosus fibrosis		
IV	Complete urethral stricture (>2cm) with extension of fibrosis beyond the corpus spongiosus and complicated by fistula, abscess, # pelvis, displacement of proximal urethra etc		

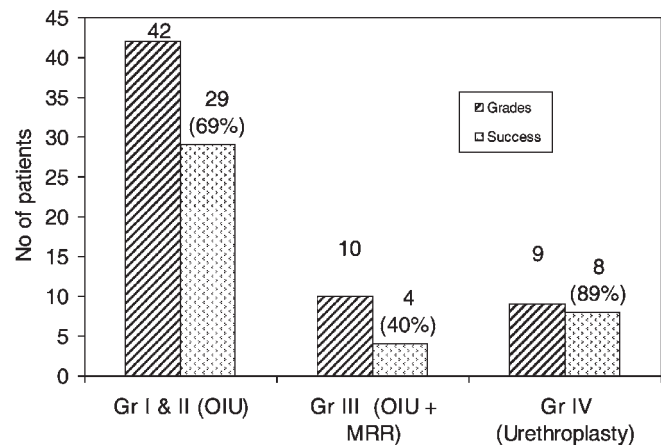
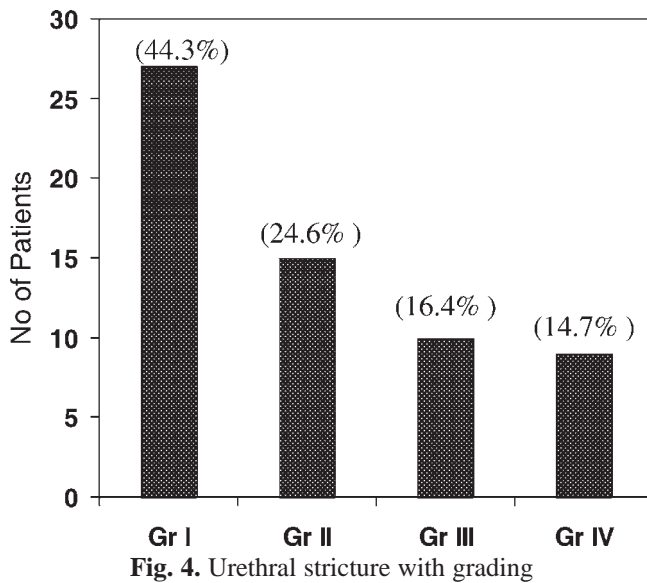


Fig. 5. Success rate of urethral stricture according to the grading and procedure

improved their voiding only in 40.0% during the 2 years follow up period (Fig. 5). Of the 10 grade III urethral strictures 5 cases were converted to urethroplasty after several attempts of residual OIU during the follow up period.

DISCUSSION

It is well established and proved by several studies that recurrence of urethral stricture is very high (40.0%-50.0%) irrespective to cause, site and severity of stricture whatever procedure is conducted to manage the stricture.⁶⁻⁸ The aetiology of recurrence of urethral stricture is not established yet however corpus spongiosum which surround the anterior urethra may be the sole cause of extensive fibrosis after a trivial injury leading to stricture formation. Corpus spongiosum is a highly vascular, honey comb like spongy structure which act as a cushion to prevent compression of urethra during the ejaculation. But, whenever it injured (greater than grade I stricture) healed by extensive fibrosis after collision of vascular septa and cause recurrence of stricture.³ Our study also supports that grade I and II urethral stricture healed well after OIU without or minimal residual fibrosis or recurrence of stricture whereas grade III stricture healed by extensive fibrosis leading to recurrence of stricture (60.0%) after modified railroading because of the extensive involvement of corpus spongiosum.

In our study cases with grade IV stricture, end to end anastomosis of urethra (anastomotic urethroplasty) after the excision of fibrous tissue had very good result (89.0%) over other types of urethroplasty.⁹⁻¹¹ In cases with pre-bulbar or membranous stricture; excision of fibrous segment, sequential mobilization of bulbous urethra and end to end anastomosis to the proximal urethra has better result than other form of urethroplasty

advocated by Mundy¹² and also supported by other authors.¹³⁻¹⁵

Grading of urethral stricture is very important in order to select the modality of treatment. To our knowledge this is the first prospective study where modality of treatment is chosen according to the grading of stricture. We follow the grading formulated by Jordan,⁴ which is based on the severity and extension of fibrosis in the corpus spongiosum. We modified the grading of stricture incorporated with ante/retrograde UCG findings (Table-1). It helps to predict severity, extension of stricture, evaluates proximal urethra / bladder and guides to lay out the urethral tract where to follow during the optical urethrotome or urethroplasty.

Outcome of urethral stricture (grade I and II) had very good result after OIU (69.0%), which is similar to the findings published by other recent series.¹⁶⁻¹⁹ We had very poor outcome in cases with grade III stricture (40.0%) which were subjected to modified railroading. Fifty percentages of such strictures were converted to urethroplasty during the follow up period. We advocate grade III stricture should undergo for urethroplasty because modified railroading by antegrade sound assisted OIU had very poor outcome and high recurrence rate (60.0%). We recently developed modified railroading by using flexible cystoscopy antegradely through suprapubic port and cut the stricture retrogradely by Sachse urethrotome (Fig. 1). The flexible cystoscopy (12 Fr) performed suprapubically, guides the proximal urethra where to cut the stricture by cold knife on seeing the glow of light distally (cut to the light technique).²⁰ This procedure is under the study and result is still awaited.

In our series, urethral dilatation by metallic dilator was not used as primary management for urethral stricture because it is a blind procedure which may cause false

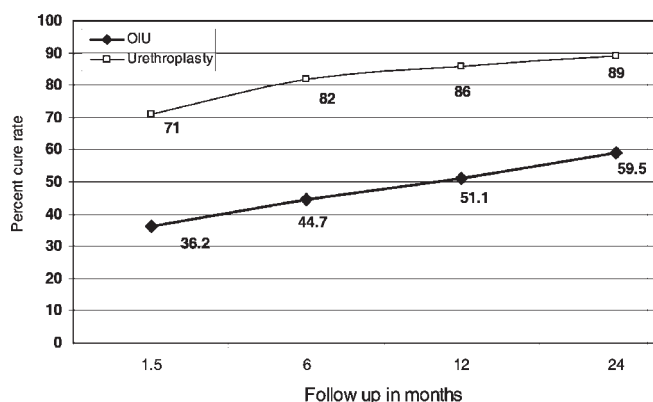


Fig. 6. Showing steady improvement of urethral stricture during the following period.

passage or further injury at the site of narrow stricture. However, this procedure was conducted after the primary treatment of the stricture for the prevention of recurrent stricture during the follow up period. Some studies have reported that follow up of urethral stricture with clean intermittent self catheterization (CISC) has good performance to maintain the urethral patency.^{18,21,22} However, in our series patient's compliance was noted very poor. It may be due to unable to follow the instruction properly by the remote village community. Our experience with stricture has shown that during the follow up period surgeon should not be impatient nor the patient; because in order to get a good result a frequent, regular and long term follow up is mandatory. At the end, a steady improvement can be achieved during the long run (Fig. 6).

Our study concludes that optical internal urethrotomy is still a gold standard procedure to manage the lower grade (I-II) stricture because it is a minimally invasive with low morbidity, can be performed as a day care procedure and success rate is about 70.0%. End to end anastomotic urethroplasty for grade IV stricture also has good result (89.0%) however success is depended upon the accurate and skilful mobilization of distal urethra in order to prevent the future chordee. However, grade III stricture may need either urethroplasty or modified railroading by flexible cystoscopy (cut to the light technique) to reduce the recurrence rate.

REFERENCES

1. Attwater HL. The History of Urethral Stricture. *Brit J Urol* 1943; 15: 39.
2. Spirnak JP, Smith EM, Elden JS. Posterior urethral obliteration treated by endoscopic reconstruction, internal urethrotomy and temporary self dilatation. *J Urol* 1993; 149: 766-8.

3. Patric C Walsh. Campbell's Urology. 9th ed. Baltimore-Maryland: Elsevier science 2007; 1054-74.
4. Jordan GH. Management of anterior urethral stricture disease. *Probl Urol* 1987; 1: 199-225.
5. Yasuda K, Yamanishi T, Isaka S *et al*. Endoscopic re-establishment of membranous urethral disruption. *J Urol* 1991; 145: 977-9.
6. Ballanger P, Midy D, Vely JF *et al*. Results of endoscopic urethrotomy in the treatment of urethral stricture. Apropos of 72 cases. *J Urol* 1983; 89: 95-9.
7. Hafez AT, El-Assmy A, Dawaba MS *et al*. Long term outcome of visual internal urethrotomy for the management of pediatric urethral strictures. *J Urol* 2005; 173: 595-7.
8. Nazir A, Ahmed M, Chughtai N *et al*. Management of post traumatic posterior urethral stricture; Internal urethrotomy verses perennial urethroplasty. *Ann King Edward Med Coll* 2005; 11: 45-7.
9. Barbagli G, Selli C, di Cello *et al*. A one-stage dorsal free-graft urethroplasty for bulbar urethral strictures. *Semin Urol* 1987; 5: 219-35.
10. Iselin C, Wbster G. Dorsal onlay urethroplasty for urethral stricture repair. *World J Urol* 1998; 16: 181-5.
11. Andrich D, Mundy A. The Barbagli procedure gives the best results for patch urethroplasty of the bulbar urethra. *Brit J Urol Int'l* 2001; 88: 385-9.
12. Mundy AR. Management of urethral stricture. *Postgrad Med J* 2006; 82: 489-93.
13. Ahmed A, Kalayi GD. Urethral stricture at Ahmadu Bello University Teaching Hospital, Zaria. *East African Med J* 1998; 75: 582-5.
14. Naude AM, Heyns CF. What is the place of internal urethrotomy in the treatment of urethral stricture disease? *Nat Clin Pract Urol* 2005; 2: 538-45.
15. Essiet A, Irekpita EE, Ekwere PD *et al*. Management of urethral strictures in the UCTH Calabar. *Niger Postgrad Med J* 2007; 14: 50-3.
16. Malik HJ, Nisar AS. Experience with cold knife optical internal urethrotomy temporary dilatation. *Pakistan J Med Res* 2002; 41: 6-9.
17. Gheorghiu V, Radu VD, Costache C *et al*. Internal urethrotomy, a modern method in the treatment of urethral strictures. *Rev Med Chir Soc Med Nat Lasi* 2003; 107: 846-50.
18. Abid B, Safdar HS, Shuja T. Optical internal urethrotomy for the treatment of urethral strictures. *Professional Med J* 2004; 11: 338-44.
19. Ramyil V, Dakum NK, Liman US *et al*. Visual Internal Urethrotomy in the Management of Anterior Urethral Stricture. *African J Urol* 2007; 13: 267-72.
20. Textbook of Operative Urology, Editor FF Marshall, WB Saunders Company. Chapter 12: 102-5.
21. Ngugi PM, Kassim A. Clean intermittent catheterization in the management of urethral stricture. *East African Med J* 2007; 84: 522-4.
22. Neel KF, Salem MA, Soliman SM *et al*. Acceptance and compliance of clean intermittent catheterization among Saudi patients. *Saudi Med J* 2008; 29: 1014-7.