

Manipulation under local anesthesia in idiopathic frozen shoulder - a new effective and simple technique

JA Khan, P Devkota, BM Acharya, NMS Pradhan, SK Shreshtha, M Singh and L Mainali

Department of orthopedics, Patan Hospital

Corresponding author: Dr. Javed Ahmad Khan, Registrar, Department of orthopedics. Patan Hospital, Lagankhel, Nepal; e-mail: drjaved123@yahoo.com

ABSTRACT

Manipulation under anesthesia has been used to speed up the recovery of frozen shoulder (FS), which is said to be a self-limiting disease. This is a randomized prospective clinical trial performed in a tertiary care hospital. Thirty-one patients with idiopathic unilateral frozen shoulder underwent suprascapular nerve block and intra-articular local anesthesia with Methyl prednisolone acetate followed by manipulation of the glenohumeral joint. Differences in range of motion and pain were assessed before manipulation and at 7 days 6 weeks and 12 weeks. Passive range of motion increased significantly for abduction, external rotation, and internal rotation. Significant decrease in visual analogue pain (VAS) scores between initial and follow-up assessments was observed. Our results revealed that manipulation under suprascapular nerve block and intra-articular local anesthesia is a very simple, safe, cost effective and minimally invasive procedure for shortening the course of an apparently self-limiting disease and can improve shoulder function and symptoms quickly.

Keywords: Suprascapular block, Frozen shoulder, Intra-articular local anesthesia.

INTRODUCTION

Frozen shoulder is a common cause of shoulder disability occurring in the 40 to 60-year-old age group and affects 2.0 to 5.0% of the general population.¹ Duplay is considered to be the first one who described in 1872, a painful, stiffening condition of the shoulder, which he termed "périarthrite scapulo-humérale". He suggested manipulation under anaesthesia as its treatment.² In 1934 Codman given the name "frozen shoulder", stating that it was characterized by insidious onset, pain near the insertion of the deltoid, inability to sleep on the affected side, painful and restricted elevation and external rotation, but normal radiological appearance.³ Later in 1945, based upon his findings of synovial changes in the glenohumeral joint Neviaser introduced the term "adhesive capsulitis".⁴ Frozen shoulder is thought to be a self limiting disease, with complete remission occurring within two years. However, Shaffer *et al* showed that 50.0% of patients treated conservatively experienced either mild pain or stiffness, or both, after an average of seven years.⁵ Etiology and the most suitable treatment of this condition is still not clear but various different modalities of treatments have been recommended and a large number of studies have demonstrated successful results. Types of treatment include supervised neglect, oral steroids, intra-articular injections, physiotherapy programmes, manipulation under anesthesia, arthroscopic capsular release and open surgical release.⁶⁻¹⁹

In this study we performed manipulation after local

infiltration of coracohumeral ligament with local anesthetic, intraarticular injection of local anesthetic and Methyl prednisolone acetate combined with suprascapular nerve block using similar solution. Technique of manipulation was also different from the conventional techniques described. After manipulation patients performed home exercises. We observed the improvement in terms of range of motion and pain relief.

MATERIALS AND METHODS

Patient selection and assessment

This is a prospective clinical trial conducted in the department of Orthopedics in a tertiary care hospital. A total of 31 patients, who came to our Out Patient Department from May 2007 to May 2008 were selected randomly using computer generated serial numbers after taking informed consent. Inclusion criteria were, age above 40 years, no preceding trauma in the same shoulder, Unilateral involvement, and contralateral normal shoulder, normal blood sugar level, normal x-ray of the shoulder. We followed the criteria used by Rizk *et al* for the diagnosis of frozen shoulder, which includes passive combined abduction less than 100 degree, external rotation of less than 50 degree and internal rotation of less than 70 degree.²⁰ The patients who did not meet the criteria were excluded from the study. Clinical assessment of both, normal and affected shoulders were done and Range of motion and pain were evaluated. Pain at rest and at extreme shoulder movements were evaluated using VAS. These were constructed of 10



Fig. 1. Premanipulation combined abduction.



Fig. 2. Premanipulation external rotation.

centimeter lines anchored at one end by '0' means no pain and at the other end '10' which means severe unbearable pain with no intermediate indications. Range of motion was assessed in standing posture using Goniometer. Combined passive abduction was evaluated by measuring the angle formed by the arm and thorax after passively abducting the shoulder (Fig.1). With the arm adducted and the elbow at the side and flexed to 90 degree, the angle formed by the forearm and the sagittal plane of the body was measured as Passive external rotation (Fig.2). Passive internal rotation of the shoulder was assessed by bringing the hand behind and determining the vertebrae level that they could reach by the thumb. All the movements were in degrees except internal rotation. Vertebral levels were given points for statistical purposes. If the thumb reaches to hip joint then the score is 1, at S1 level it is 2, at L5 it is 3, similarly L4-4, L3-5, L2-6, L1-7, T12-8, T11-9, T10-10, T9-11, T8-12, T7-13, T6-14, and T5-15.

Techniques

All injections were administered by the same doctor. All the procedure was done in the Out patient

Department (OPD) in a separate room maintaining aseptic conditions as required for minor surgical procedure.

Intra-articular injection

A mixture of 40 mg of Depot methyl prednisolone, 7 ml of 1% xylocaine and 4 ml 0.5% Bupivacaine was introduced into the glenohumeral joint using a 21G 1.5" needle via anterior approach. Patient was put supine and the affected shoulder was prepared with povidone iodine solution. Coracoid process was palpated, the needle was inserted one centimeter inferolateral to the coracoid (Fig.3). The coracohumeral ligament was infiltrated with 2 ml of mixed solution. The same needle was then directed in the joint and 10 ml of solution was injected.

Suprascapular nerve block

A mixture of 40 mg of Depot methyl prednisolone, 5 ml xylocaine 1% and 4 ml 0.5% bupivacaine was injected using the technique described by Dangoisse *et al* (Fig.4).²¹ A 21G ?

1.5" needle was introduced through the skin 2 cm cephalad to the midpoint of the spine of the scapula. The needle was advanced parallel to the blade of the scapula until bony contact was made in the floor of the Suprascapular fossa where whole of the 10 ml solution was injected. This technique has previously been demonstrated to be safe and can be used to effectively block the articular branches of the suprascapular nerve.

Table-1: Range of motion normal shoulder compared with affected shoulders.

Observations	Affected shoulders	Normal shoulders	Significance (Two tailed)
External rotation*	16.71	74.2	0.00
Internal rotation#	2.2	13.45	0.00
Abduction*	58.77	160.03	0.00

* In degrees, abduction is combined abduction.

Internal rotation expressed in numerical value from 1 to 15.

Expressed as numerical value in visual analogue scale.

Table-2: Range of motion and pain before and after one week of manipulation.

Observations	Premanipulation (n=31)	Postmanipulation one week (n=31)	Significance (Two tailed)
External rotation*	16.70	41.61	0.000
Internal rotati #	2.19	6.58	0.000
Abduction*	58.77	153.42	0.000
Pain at rest##	5.87	5.16	0.003
Pain at movement#	6.61	6.67	0.763

* In degrees, abduction is combined abduction.

Internal rotation expressed in numerical value from 1 to 15.

##Expressed as numerical value in visual analogue scale.

Manipulation

After 10 minutes, when the desired effect of the local anesthetic was achieved, manipulation was first done with the patient supine. With the shoulder adducted and the elbow extended, the distal arm was held by the surgeon to perform passive external and internal rotation of the shoulder (Fig.5). Each movements were held for 10 seconds and repeated for 10 times each. Now patient was asked to clamp both the hands in front of the chest. With the help of the sound hand patient was asked to lift affected arm over the head (Fig.6a). Patients could comfortably bring the arm over head without much pain. The limb was kept in the same position for 2 minutes. Now the patient was asked to put both hands behind the head and asked to gradually bring the elbows to the level of the bed to gain external rotation (Fig.6b). In some anxious patients the surgeon needed to assist this movement by gently pushing with the index finger. Then the patient was asked to sit on the bed and repeat the same movement at least 5 times. In sitting position patient was asked to touch the scapula with the help of other hand so as to gain internal rotation. Immediate post manipulation evaluation of Range of Motion was done.

Analgesia and home exercises

Patients were discharged with Indomethacin 25 mg thrice daily, Omeprazole 20 mg twice daily and Amitriptyllin

10mg at bed time for 7 days. Additional 20 tablets of Paracetamol 500mg was also given to relieve pain on SOS basis. All patients were given verbal and written instructions regarding a home exercise program. Patients were advised to continue same manipulation movements at home at least 10 repetitions three times a day. They were not referred to physiotherapy department for additional therapy.

Follow-up and data analysis

We followed up patients after one week, six weeks and 12 weeks after the procedure. All the data were processed using SPSS for windows 11.5.

RESULTS

Total of 31 patients ranging from 40 years to 72 years (mean 50.38) were evaluated, out of which 32.3% were female and 67.7% were male. Frozen Shoulder affected in 71% of non dominant shoulder.

A marked restriction of shoulder active ROM was observed in Frozen Shoulder patients before the procedure. Patients also showed a reduction ($p < 0.05$) in active shoulder internal rotation, external rotation and abduction of involved shoulder compared to cotralateral normal shoulders before the procedure (Table-1).

After 1 week of the procedure, the score of shoulder

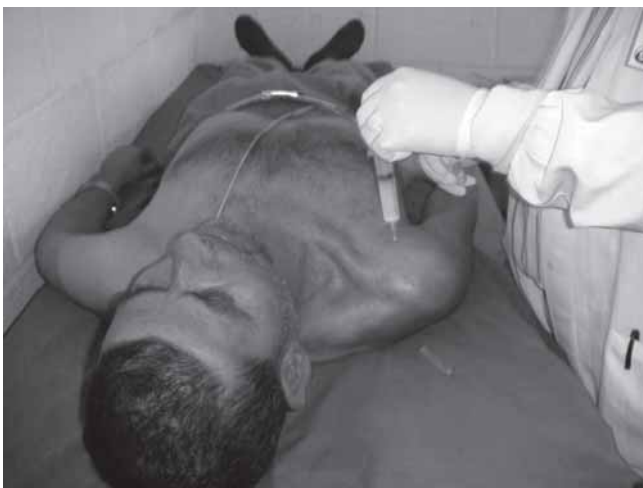

Fig.3. Intra-articular injection through anterior approach.

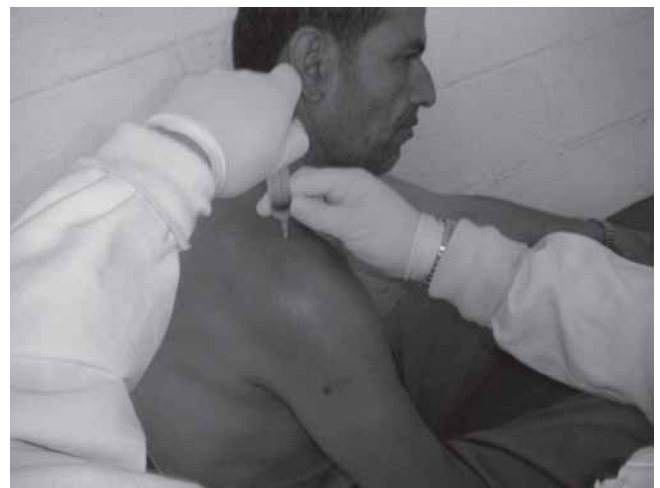

Fig. 4. Suprascapular nerve block.

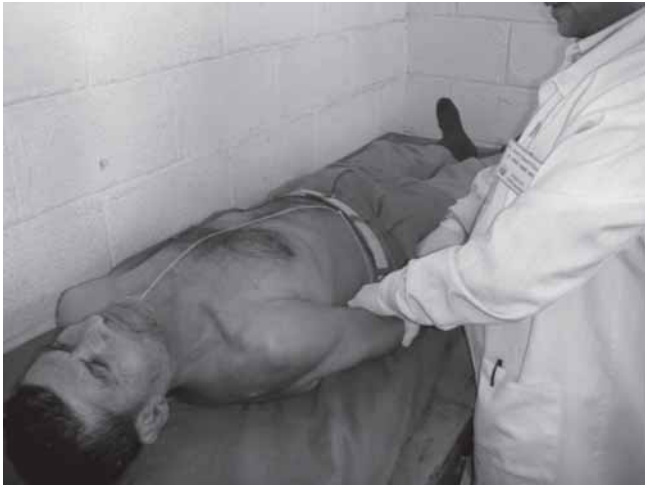


Fig.5. Manipulation technique.

internal rotation, external rotation and abduction active ROM in FS patients for involved extremity were increased ($p < 0.05$) compared with the pre-procedure level (Fig.1, Fig.7a and b). Although, pain at rest was decreased ($p < 0.05$) but pain at activity was not decreased ($p > 0.05$) (Table-2).

After 12 week after the procedure, the score of shoulder internal rotation, external rotation and abduction active ROM in FS patients for involved extremity were increased ($p < 0.05$) compared with the pre-procedure level. Both pain at rest and at activity were markedly decreased ($p < 0.05$) (Table- 3).

Following the procedure with the home exercise program there was steady improvement in the range of motion as well as reduction in the pain score (Table-4).

DISCUSSION

Frozen shoulder is a common condition seen in the out patient department characterized by pain and stiffness of shoulder. Though it is considered to be a self limiting disease but the course of disease is protracted and there

is some limitation of movement.^{22,5} Patho-physiology seems obscure but certain facts has been discovered.

In frozen shoulder, the main anatomical change is the thickening of coraco-humeral ligament. The coracohumeral and superior glenohumeral ligaments are considered to be structural contents of the rotator interval capsule, but each have separate origins and insertions.²³ Neer *et al.* observed, in a cadaver study, that release of the coracohumeral ligament increased external rotation both with the arm at the side and with it in 90 degrees of forward elevation.²⁴ Several authors have recommended release of the coracohumeral ligament, to increase glenohumeral motion, when a frozen shoulder is treated with open release.²³⁻²⁵ The interval capsule plays a major role in the range of certain motions, in the oblique translation, and in the allowed translation of the glenohumeral joint. The magnitude of these effects varied among shoulders, but the direction of the effect was consistent. Sectioning of the interval capsule increased the ranges of flexion, extension, adduction, and external rotation, and imbrication decreased these ranges of motion. Positions of abduction and internal rotation relaxed the interval capsule.^{19,26} this ligament restrains the joint in external rotation when shoulder is adducted. In our technique we performed gentle but firm external and internal rotation movements to stretch the shoulder capsule gently. We also infiltrated the coracohumeral ligament with 2 ml of local anesthetic mixture to anesthetized the ligament at the time of manipulation.

There is always pain and stiffness in the shoulder which altogether produces vicious circle leading to progressive stiffness. The pain in frozen shoulder is neither typical of inflammatory pain nor of neurogenic type which is more severe during night.²⁷ These suggest of it being related to Complex Regional Pain Syndrome.²⁸ The suprascapular nerve supplies sensory fibres to about 70%

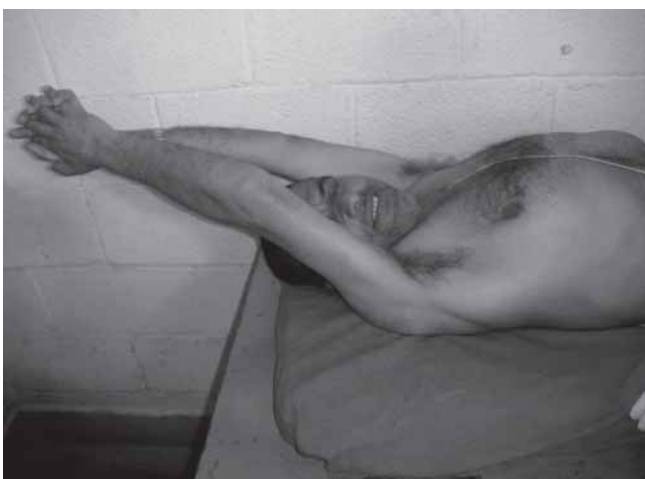

Fig. 6a. Patient controlled range of motion (flexion and abduction) exercises immediately after injections.

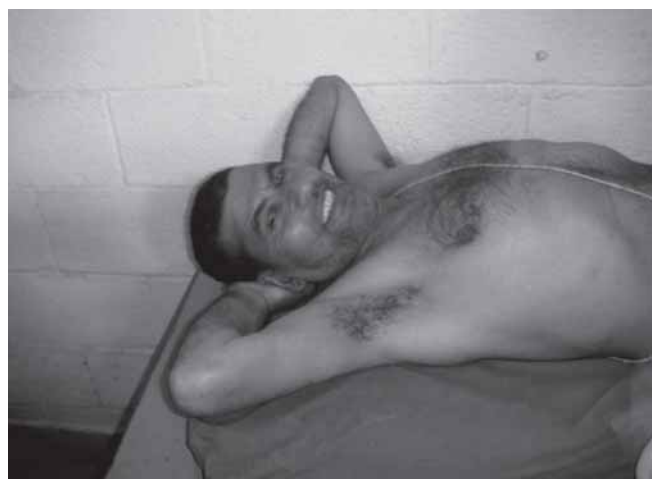


Fig. 6b. Patient controlled range of motion (Abduction and external rotation) exercises immediately after injections.

Table-3: Range of motion and pain 12 weeks after manipulation.

Observations	Preoperative (n=31)	Post manipulation 12 weeks (n=31)	Significance (Two tailed)
External rotation*	16.70	60.70	0.000
Internal rotatio #	2.19	12.74	0.000
Abduction*	58.77	168.65	0.000
Pain at rest##	5.87	0.22	0.000
Pain at movement##	6.61	0.25	0.000

* In degrees, abduction is combined abduction.

Internal rotation expressed in numerical value from 1 to 15.

Expressed as numerical value in visual analogue scale.

of the shoulder joint, including the superior and posterosuperior regions of the shoulder joint and capsule, and the acromioclavicular joint.²⁹ We blocked suprascapular nerve using three different drugs with different actions. Xylocaine relieved pain immediately, Bupivacaine worked for 24 to 72 hours after that methyl prednisolone worked for weeks. Literature shows addition of glucocorticoids in local anesthetic blocks transmission of nociceptive c fibers. The block prolonging effect of steroid is due to its local effect. The action of steroid has been related with the alteration of functions of potassium channel on the excitable tissue.³⁰⁻³³

As the direct action of Bupivacaine cannot extend beyond a few hours or days there must be an effect of Depot methyl prednisolone on the underlying pathology, which owes in part to the patient's ability to perform an adequate exercise program.

All the manipulations were active and assisted. No passive manipulations were done as passive stretching of the joint produces pain which evokes reflex contraction of antagonistic muscles. After completion of the manipulation the patients were asked to bring the affected limb over the head with the help of the other

hand. All the range of movements were performed by patients themselves at home. Thus all range of motions were possible without significant pain, sometimes an audible pop could be heard as a result of breakage of adhesions. Patients were able to perform the same assisted active range of motion exercise at home regularly without pain. Study done by Ronald L. Diercks, showed that result of intensive physiotherapy involving stretching exercises up to pain threshold is worse than supervised neglect 64.0% verses 90.0%.⁶

Most noninvasive therapeutic strategies are based on stretching or rupturing the tight capsule by manipulative physical therapy with success rate for achieving good to fair results nearing 100.0%.^{7,28,34} The good result of physical therapy with intraarticular corticosteroid injections, with or without hydraulic distension, ranges from 44.0% to 80.0%.³⁵⁻³⁸ More aggressive interventions, such as manipulation under anesthesia and arthroscopic or open release, are a popular form of therapy especially for resistant frozen shoulder. The published success rate for this therapy varies 69% to 97.0%.^{14,39-41} The study of using Suprascapular nerve block for frozen shoulder showed improvement in pain and range of motion in 79.0% of patients at 12 weeks.⁴²




Fig. 7a. One week follow up.




Fig. 7b. One week follow up.

Table-4: Master table showing range of motion before and after each follow-ups.

Time	Abduction	External rotation	Internal rotation	Pain at rest	Pain at activity
Initial	58.77	16.70	2.19	5.87	6.61
Week1	153.42	41.61	6.58	5.16	6.67
Week6	163.29	51.16	8.22	0.61	1.19
Week12	168.65	60.70	12.74	0.22	0.25

In this study we used a combined approach (Intraarticular injection of local anesthesia with corticosteroid plus coracohumeral infiltration plus Suprascapular nerve block plus gentle manipulation and active assisted range of motion exercises) to the management of FS. We have achieved significant improvements in the range of motion as well as relief of pain in our patients. We also prescribed low dose amitriptyline which is effective in reducing night pain and effective in pain associated with complex regional painful syndrome.

The only adverse effect during the course of the trial was with one patient who experienced a vaso-vagal collapse following an intra-articular injection. She recovered promptly after maintaining supine posture for 15 minutes.

We conclude that Intraarticular injection of local anesthesia with corticosteroid plus coracohumeral infiltration plus suprascapular nerve block plus gentle manipulation and active assisted range of motion exercises speeds the recovery of idiopathic frozen shoulders and quickly improves shoulder function. This combined approach is a safe and

is reasonably effective for treatment of idiopathic frozen shoulder in non-diabetic patients. This needed to prove with longer follow-ups and involving larger sample.

REFERENCES

1. Wolf JM, Green A. Influence of comorbidity on self Vassessment instrument scores of patients with idiopathic adhesive capsulitis. *J Bone Joint Surg* 2002; 84-A : 1167-72.
2. Duplay S. De la péri-arthritis scapulo-humérale et des raideurs de l'épaule qui en sont la conséquence. *Arch Gen Med* 1872; 20: 513-42.
3. Codman EA. The Shoulder: rupture of the supraspinatus tendon and other lesions in or about the subacromial bursa. Boston, 1934.
4. Neviasser JS. Adhesive capsulitis of the shoulder: a study of the pathological findings in periartthritis of the shoulder. *J Bone Joint Surg* 1945; 27: 211-22.
5. Shaffer B, Tibone JE, Kerlan RK. Frozen shoulder: a long-term follow-up. *J Bone Joint Surg* 1992; 74-A: 738-46.
6. Diercks RL, Stevens M. Gentle thawing of the frozen shoulder: A prospective study of supervised neglect versus intensive physical therapy in seventy-seven patients with frozen shoulder syndrome followed up for two years. *J Shoulder Elbow Surg* 2004; 13: 499-502.
7. Miller MD, Wirth MA, Rockwood CA Jr. Thawing the frozen shoulder: The "patient" patient. *Orthopedics* 1996; 19: 849-53.

8. Buchbinder R, Hoving JL, Green S *et al.* Short course prednisolone for adhesive capsulitis (frozen shoulder or stiff painful shoulder) : a randomised, double blind, placebo controlled trial. *Ann Rheum Dis* 2004; 63: 1460-9.
9. Rhind V, Downie WW, Bird HA *et al.* Naproxen and Indomethacin in periartthritis of the shoulder. *Rheumatol Rehabil* 1982; 21: 51-3.
10. Ryans I, Montgomery A, Galway R *et al.* A randomized controlled trial of intra-articular triamcinolone and/or physiotherapy in shoulder capsulitis. *Rheumatology* 2005; 44: 529-35.
11. Carette S, Moffet H, Tardif J *et al.* Intraarticular corticosteroids, supervised physiotherapy, or a combination of the two in the treatment of adhesive capsulitis of the shoulder. *Arthritis Rheum* 2003; 48: 829-38.
12. Griggs SM, Ahn A, Green A. Idiopathic adhesive capsulitis: A prospective functional outcome study of nonoperative treatment. *J Bone Joint Surg* 2000; 82-A : 1398-1407.
13. Jürgel J, Rannama L, Gapeyeva H *et al.* Shoulder function in patients with frozen shoulder before and after 4-week rehabilitation. *Medicina (Kaunas)* 2005; 41: 30-8.
14. Dödenhoff RM, Levy O, Wilson A, Copeland SA. Manipulation under anaesthesia for primary frozen shoulder: effect on early recovery and return to activity. *J Shoulder Elbow Surg* 2000; 9: 23-6.
15. Farrell CM, Sperling JW, Cofield RH. Manipulation for frozen shoulder: Long-term results. *J Shoulder Elbow Surg* 2005; 14: 480-4.
16. Berghs BM, Sole-Molins X, Bunker TD. Arthroscopic release of adhesive capsulitis. *J Shoulder Elbow Surg* 2004; 13: 180-85.
17. Segmuller HE, Taylor DE, Hogan CS *et al.* Arthroscopic treatment of adhesive capsulitis. *J Shoulder Elbow Surg* 1995; 4: 403-4.
18. Omari A, Bunker TD. Open surgical release for frozen shoulder: Surgical findings and results of the release. *J Shoulder Elbow Surg* 2001; 10: 353-7.
19. Ozaki J, Nakagawa Y, Sakurai G, Tamai S. Recalcitrant chronic adhesive capsulitis of the shoulder. Role of contracture of the coracohumeral ligament and rotator interval in pathogenesis and treatment. *J Bone Joint Surg* 1989; 71-A: 1511-5.
20. Rizk TE, Pinals RS. Frozen shoulder. *Semin Arthritis Rheum* 1982; 11: 440-52.
21. Dangoisse MJ, Wilson DJ, Glynn CJ. MRI and clinical study of an easy safe technique of suprascapular nerve blockade. *Acta Anaesth Belg* 1994; 45: 49-54.
22. Binder AI, Bulgen DY, Hazleman BL, Roberts S. Frozen shoulder: a long-term prospective study. *Ann Rheum Dis* 1984; 43: 361-4.
23. DePalma, A. F.: *Surgery of the Shoulder*. Ed. 3. Philadelphia. B. Lippincott, 1983.
24. Neer CS, Satterlee CC, Dalsey RM, Flatow EL. On the value of the coracohumeral ligament release. *Orthop Trans* 1989; 13: 235-6.

25. Leffert RD. The frozen shoulder. In Instructional Course Lectures, The American Academy of Orthopaedic Surgeons. Vol. 34, pp. 199-203. St. Louis, C. V. Mosby, 1985.
26. Harryman DT, Sidles JA, Harris SL, Matsen FA. The role of the rotator interval capsule in passive motion and stability of the shoulder. *J Bone Joint Surg Amer* 1992; 74: 53-66.
27. Woolf CJ. Somatic pain pathogenesis and prevention. *Brit J Anaesth* 1995; 75: 169-76.
28. Muller LP, Rittmeister M, John J, Happ J, Kerschbaumer F. Frozen shoulder—an algoneurodystrophic process? *Acta Orthop Belg* 1998; 64: 434-40.
29. Ritchie ED, Tong D, Chung F, Norris AM, Miniaci A, Vairavanathan SD. Suprascapular nerve block for postoperative pain relief in arthroscopic surgery: a new modality? *Anesth Analg* 1997; 84: 1306-12.
30. Johanson A, Hao J. Local corticosteroid application blocks transmission in nociceptive c fibers. *Acta Anesthesiologica Scand* 1990; 34: 335-8.
31. Shrestha BR, Maharjan SK, Shrestha S et al. Comparative study between Tramadol and Dexamethasone as an admixture to Bupivacaine in Supraclavicular. *Brachial Plexus Block* 2007; 46: 158-64.
32. Castillo J, Curley J, Hotz J et al. Glucocorticoids prolong rat sciatic nerve blockade in vivo from bupivacaine microspheres. *Anesthesiol* 1996; 85: 1157-66.
33. Lundberg J. The frozen shoulder. Clinical and radiographical observations. The effect of manipulation under general anesthesia. Structure and glycosaminoglycan content of the joint capsule. Local bone metabolism. *Acta Orthop Scand* (Suppl 119): 1-59.
34. Goupille P, Sibilia J. Local corticosteroid injections in the treatment of rotator cuff tendinitis (except for frozen shoulder and calcific tendinitis). Groupe Rhumatologique Francais de l'Epaule (G.R.E.P.). *Clin Exp Rheumatol* 1996; 14: 561-6.
35. Ritzmann P. "Frozen shoulder:" intraarticular corticosteroids lead to faster pain relief than physiotherapy [in German]. *Schweiz Rundsch Med Prax* 1999; 88: 1369-70.
36. Steinbrocker O, Argyros TG. Frozen shoulder: treatment by local injections of depot corticosteroids. *Arch Phys Med Rehabil* 1974; 55: 209-13.
37. Fareed DO, Gallivan WR Jr. Office management of frozen shoulder syndrome. Treatment with hydraulic distension under local anesthesia. *Clin Orthop* 1989; 242: 177-83.
38. Hsu SY, Chan KM. Arthroscopic distension in the management of frozen shoulder. *Int Orthop* 1991; 15: 79-83.
39. Ha'eri GB, Maitland A. Arthroscopic findings in the frozen shoulder. *J Rheumatol* 1981; 8: 149-52.
40. Haines JF, Hargadon EJ. Manipulation as the primary treatment of the frozen shoulder. *J Roy Coll Surg Edinb* 1982; 27: 271-5.
41. Pearsall AW, Osbahr DC, Speer KP. An arthroscopic technique for treating patients with frozen shoulder. *Arthroscopy* 1999; 15: 2-11.
42. Jones DS, Chattopadhyay C. Suprascapular nerve block for the treatment of frozen shoulder in primary care: a randomized trial. *Brit J General Practice* 1999; 49: 39-41.