

Recurrent Abdominal Pain In Children: The Role Of Upper Gastro Intestinal Endoscopy

Upadhyay S, Sharma A, Kumar P

Department of Pediatrics, Nepal Medical College Teaching Hospital, Kathmandu

Corresponding Author: Dr. Satyam Upadhyay, MD Pediatrics, Fellowship (Pediatric gastroenterology) Assistant Professor, Department of Pediatrics, Nepal Medical College And Teaching Hospital, Attarkhel, Jorpati, Kathmandu, Nepal; e-mail: rimalsatyam@gmail.com

ABSTRACT

Abdominal pain is a common gastrointestinal symptom in children. Recurrent abdominal pain (RAP) affects 34% of world's population and prevalence of RAP in school going children ranges between 10-20%. Recurrent abdominal pain (RAP) refers to episodes of abdominal pain which is severe enough to implicate the daily activity of a child. It is defined as three or more bouts of abdominal pain in at least three-month period. Before the introduction of Upper GI endoscope, the majority of RAPs were categorized as functional pain with psychogenic sources. However, after the advent of pediatric endoscopes in 1970s, organic etiologies gradually became more prominent and reached to greater proportions. This Prospective observational study was conducted in children undergoing upper GI endoscopy for recurrent abdominal pain at NMCTH from November 2014 to April 2016 (18 months). A total of 64 children with RAP were recruited. The average age was 10.2 years and 38 (59%) were female. Forty-six (71.8%) were diagnosed to have an organic etiology for their RAP, while 18 had a non-organic cause. Antral gastritis was observed in 28 (43.7%), duodenitis in 8(12.5%), esophagitis in 4 (6.2%), prepyloric ulcer in 3(4.6%) and fundal gastritis in 3(4.6%) patients. Antral and duodenal biopsy was taken in all patients. The most common organic etiology of RAP was *Helicobacter Pylori* infection and was seen in 10(30%) patients who had antral gastritis and giardia lamblia in 4(50%) patients who had duodenitis. The most common non-organic cause of RAP was labeled as functional abdominal pain 18(28.2%). The gastric antrum was the most common site of abnormal endoscopic findings. Organic causes of RAP in children are increasingly identified in our institute. Upper GI endoscopy proved to be very useful in the evaluation of our patients who presented with clinically-significant RAP. Once the diagnosis was established, specific treatment improved and cured the RAP symptoms.

Keywords: Upper GI Endoscopy, Recurrent abdominal pain

INTRODUCTION

Abdominal pain is a common gastrointestinal symptom in children.¹ Recurrent abdominal pain(RAP) affects 34% of world's population and prevalence of RAP in school going children ranges between 10-20%.² Recurrent abdominal pain (RAP) refers to episodes of abdominal pain which is severe enough to implicate the daily activity of a child. It is defined as three or more bouts of abdominal pain in at least three-month period.³ Before the introduction of Upper GI endoscope, the majority of RAPs were categorized as functional pain with psychogenic sources.⁴ However, after the advent of pediatric endoscopes in 1970s, organic etiologies gradually became more prominent and reached to greater proportions. RAP has a diverse etiology according to place and local conditions. The etiology and pathogenesis of recurrent abdominal pain in Nepali scenario are not well known and seem to be labeled as functional

abdominal pain. Esophagogastroduodenoscopy (EGD) is a well established diagnostic and therapeutic procedure in RAP in pediatric patients¹. This important diagnostic tool helps us to differentiate organic cause from functional abdominal pain in children. In recent times, organic etiologies are responsible for 10% to 50% of RAPs.⁵ This study has tried to look into the organic etiology of RAP in children.

MATERIALS AND METHODS

This Prospective observational study was conducted in children undergoing upper GI endoscopy for recurrent abdominal pain at NMCTH from November 2014 to April 2016 (18 months). The study protocol was approved by the Research Ethics Committee of Nepal Medical College & Teaching Hospital. Written informed consent was obtained from all participating subjects. Children aged 5 years to 15 years presenting with

recurrent abdominal pain were included in the study who had unremarkable physical examination, complete blood count, stool and urine routine and microscopy and ultrasound abdomen. Written consent was taken prior to endoscopy. Patients were asked to fast for four to six hours prior to endoscopy. Single dose of Intravenous midazolam 0.1mg/kg and intravenous Ketamine 1-2mg/kg was given. Flexible fibreoptic pediatric upper GI (Karl Storz 5.9 mm) endoscope was used. Findings were registered and biopsy from a minimum of two sites including antrum and second part of duodenum were obtained and sent for histopathological examination.

RESULT

A total of 70 children with RAP were initially included into the study. Six of them refused endoscopy. Therefore, the final study group consisted of 64 children. The average age was 10.2 years and 38 (59%) were female. (Fig 1)

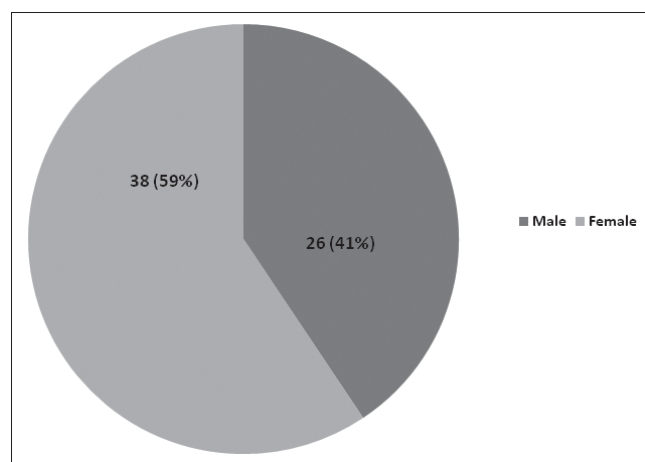


Fig 1: Gender distribution of children who underwent UGI endoscopy for RAP

Forty-six (71.8%) were diagnosed to have an organic etiology for their RAP, while 18 had a non-organic cause. (Table 1) Antral gastritis was observed in 28 (43.7%), duodenitis in 8(12.5%), esophagitis in 4 (6.2%), prepyloric ulcer in 3(4.6%) and fundal gastritis in 3(4.6%) patients. Antral and duodenal biopsy was taken in all patients. The most common organic etiology of RAP was *Helicobacter Pylori* infection and was seen in 10(30%) patients who had antral gastritis and giardia lamblia in 4(50%) patients who had duodenitis. The most common non-organic cause of RAP was labeled as functional abdominal pain 18(28.2%). The gastric antrum was the most common site of abnormal endoscopic findings.

Table 1: Findings of UGI endoscopy in RAP

Endoscopic findings	Number (%)
Antral gastritis	28(43.7%)
Duodenitis	8(12.5%)
Esophagitis	4(6.2%)
Prepyloric ulcer	3(4.6%)
Fundal gastritis	3(4.6%)
Normal	18(28.2%)

The presence of an endoscopic abnormality was strongly associated with an organic cause of RAP. Chronic moderate to severe follicular gastritis was the most common finding¹⁹, followed by chronic mild gastritis⁹. In the subgroup of patients with *Helicobacter pylori* infection, the endoscopic abnormalities were antral erosions (3 cases) and antral erythema.⁷ Duodenal nodularity and scalloping were the most common endoscopic findings in the duodenum 8(12.5%) and 4 of them had giardia lamblia infection. Esophagitis was seen in 4 cases and was likely to be due to hiatus hernia which was seen in all cases.

All patients received treatment according to their specific diagnosis and none has shown recurrence of the RAP symptoms during the follow-up period. Children with *Helicobacter pylori* infection were treated with omeprazole, amoxicillin, and clarithromycin for 14 days. Children with giardiasis received Metronidazole for 10 days.

DISCUSSION

The entity known as RAP in children was first described by Apley and Naish in 1958.⁶ The incidence found in their community-based study was 10.8% and the majority of cases were diagnosed as non-organic.⁶ This and other studies described an association between RAP and emotional disturbances, including over-concern of illnesses in family members, neuroticism, and maternal anxiety disorder.^{6,7-9} The postulated mechanism is that imitation of illnesses and inappropriate response to emotional stresses in children could lead to psychosomatic symptoms, such as abdominal pain.¹⁰ Croffie¹¹ further confirmed that most children with RAP had a functional disorder and suggested that cost-effectiveness evaluations should be carefully considered. McGrath *et al*,¹² on the other hand, found no difference between a group of children with RAP and a control group in terms of stressful events, extreme personality characteristics, and imitation of abdominal pain from the family members, thus contradicting the perception that the majority of RAP in children had a psychogenic origin. Similarly, a study by Raymer,¹³ failed to find

an emotional disturbance that could significantly differentiate

between organic and non-organic RAP. With the advent of pediatric endoscopy, more studies have reported organic causes of RAP.¹⁴⁻¹⁶ Although our study evaluated a select population of children referred to our institute and may not represent the true incidence in general population, we found that almost three-fourth of the cases with RAP (71.8%) had an organic cause. A similar study was conducted in Northern Thailand by Ukarapol N¹⁷ and Aanpreung P¹⁸. They were able to demonstrate organic causes of RAP in 44.7% and 51.6% of children respectively. Another study done by Joshi MR at Kathmandu medical college teaching hospital, Out of 26 cases of recurrent abdominal pain, 8 cases (30%) had significant positive finding in endoscopic examination.¹⁹ Antral Gastritis was the most common endoscopic finding 28(43.7%) and *Helicobacter pylori* infection was the most common etiology of RAP in our study 10 (35%), followed by parasitic infestations (*Giardia lamblia*). This finding was comparable to the study done by Ukarapol N *et al.*¹⁷ The authors found *Helicobacter pylori* infection as the most common cause and concluded that upper endoscopy was very helpful in identifying the underlying pathology. *Helicobacter pylori* infection in children was significantly associated with antral erythema and erosions that histologically contained lymphoid follicles, and chronic moderate to severe active gastritis. Our observation that all our infected patients improved once antimicrobial therapy was administered suggests a possible link.

In conclusion, organic causes of RAP in children are increasingly identified in our institute. Upper GI endoscopy proved to be very useful in the evaluation of our patients who presented with clinically-significant RAP. Once the diagnosis was established, specific treatment improved and cured the RAP symptoms.

REFERENCES:

1. Mark A G. Gastroenterologic endoscopy in children: past, present and future. *Current opinion in Pediatrics* 2001;13:429-34
2. Ramchandani PG, Hotopf BM, Sandhu A. The epidemiology of Recurrent Abdominal pain from 2 to 6 years of age: Result of a large, population-based study. *Pediatrics* 2005;116:46-50
3. Apley J. Upper endoscopic findings in children with recurrent abdominal pain. *Br J Clin Pract.* 1959;13:586-7
4. Boyle JT. Recurrent abdominal pain, an update. *Pediatr Rev* 1997; 18:310-20
5. Stordal K, Nygaard EA, Bentsen BS. Recurrent abdominal pain: a five-year follow-up study. *Acta Paediatr* 2005; 94:234-6
6. Apley J, Naish N. Recurrent abdominal pains: a field survey of 1000 school children. *Arch Dis Child* 1958; 33:165-70
7. Hotopf M, Carr S, Mayou R, Wadsworth M, Wessely S. Why do children have chronic abdominal pain, and what happens to them when they grow up? A population based cohort study. *Br Med J* 1998; 316:1196-2000
8. Apley J, Hale B. Children with recurrent abdominal pain: how do they grow up? *Br Med J* 1973; 3:7-9
9. Christensen MF, Mortensen O. Long-term prognosis in children with recurrent abdominal pain. *Arch Dis Child* 1975; 50:110-4
10. Compas BE, Thomsen AH. Coping and responses to stress among children with recurrent abdominal pain. *J Dev Behav Pediatr* 1999;20:323-4
11. Croffie JM, Fitzgerald JF, Chong SKF. Recurrent abdominal pain in children – a retrospective study of outcome in a group referred to a pediatric gastroenterology practice. *Clin Pediatr* 2000; 39:267-74
12. McGrath PJ, Goodman JT, Firestone P, Shipman R, Peters S. Recurrent abdominal pain: a psychogenic disorder? *Arch Dis Child* 1983; 58:888-90
13. Raymer D, Weininger O, Hamilton JR. Psychological problems in children with abdominal pain. *Lancet* 1984; 1:439-40
14. Mavromichalis I, Zaramboukas T, Richman PI, Slavin G. Recurrent abdominal pain of gastro-intestinal origin. *Eur J Pediatr* 1992; 151:560-3
15. Roma E, Panayiotou J, Kafritsa Y, Van-Vliet C, Gianoulia A, Constantopoulos A. Upper gastrointestinal disease, *Helicobacter pylori* and recurrent abdominal pain. *Acta Paediatr* 1999; 88:598-601
16. Stordal K, Nygaard EA, Bentsen B. Organic abnormalities in recurrent abdominal pain in children. *Acta Paediatr* 2001; 90:638-42
17. Ukarapol N, Lertprasertsuk N, Wongsawasdi L. Recurrent abdominal pain in children: the utility of upper endoscopy and histopathology. *Singapore Med J.* 2004; 45:121-4
18. Aanpreung P, Atisook K, Suwanagool P, Vajjaradul C. Upper gastrointestinal endoscopy in children with recurrent abdominal pain. *J Med Assoc Thai* 1997; 80:22-5
19. Joshi MR, Sharma SK, Baral MR. Upper GI Endoscopy in Children- in an adult suite. *Kathmandu University Medical Journal* 2005; 3:111-114