

Trans-septal suturing following septoplasty: an alternative for nasal packing

A Ghimire, TR Limbu and R Bhandari

Department of Otolaryngology & Head Neck Surgery, Chitwan School of Medical Sciences, Bharatpur, Nepal

Corresponding author: Dr. Anand Ghimire, Associate Professor, Department of Otolaryngology & Head Neck Surgery, Chitwan School of Medical Sciences, Bharatpur, Nepal; e-mail: anand_ghi@yahoo.com

ABSTRACT

Septoplasty is one of the most common otorhinolaryngologic surgical procedure. It is customary to place a pack in the nose as a part of nasal surgery to stop bleeding, enhance apposition of mucosal flaps, and stabilize the operated septal cartilage and bones. But nasal packing is not an innocuous procedure. The most common problem encountered by the patients after septoplasty with nasal pack is the pain and discomfort in post operative period. The study has been performed to compare the complications and outcome of septoplasty with or without nasal packing. Forty four patients were randomly allocated into two groups, Group A ($n=21$) and Group B ($n=23$). In Group A trans-septal suture and in Group B intranasal pack was used following septoplasty. Both groups were compared for postoperative pain, postoperative complications and surgical outcome. Among 44 patients 31 patients were male and 13 patients were female. Most of the patients ie 79.5% were operated for nasal obstruction. Only one patient had postoperative nasal bleeding requiring nasal pack in Group A. Higher Postoperative pain score, longer hospital stay and more complications were observed in Group B patients. No difference was found in patients' satisfaction after the operation. Septoplasty can be safely performed without postoperative nasal packing and is preferred to avoid postoperative pain, discomfort and other complications.

Keywords: Nasal pack, septoplasty, transeptal suture.

INTRODUCTION

Septoplasty, one of the most common operations performed in otolaryngology, has evolved from the ancient times until today and nasal passages have been packed as a fundamental step of the surgery to prevent bleeding, formation of synechiae, and septal hematoma. In addition, nasal packing has been used for internal stabilization following operations on the cartilaginous and bony skeleton of the nose. But post-operative pain, mucosal injury, worsening of breathing due to sleep disorders, displacement and aspiration of the packing material, and postoperative infections are the complications associated with nasal packing.

As an alternative application to nasal packing, different forms of haemostatic suturing techniques of the nasal septum have been described. Currently, trans-septal sutures have gained a broader application area.

In present study septoplasty performed with trans-septal suturing was compared with septoplasty with nasal packing to assess its outcomes and post-operative complications.

MATERIALS AND METHODS

Forty four patients were included in this study who had symptomatic deviated nasal septum (DNS) and underwent septoplasty from May 2009 to April 2011 in Chitwan

School of Medical sciences and Maula-Kalika Hospital. All operations were performed under general anaesthesia. Surgery proceeded using the submucosal approach to the deviated segment of the septum via a closed approach starting with a hemitransfixation incision and the correction of the deviated segment with minimal excisions. The incisional line was closed by 3-0 catgut. At the end of the operation in twenty one patients (Group A) two to three trans-septal sutures were applied to approximate the mucosal flaps without any nasal packing and in 23 patients (Group B) antibiotic impregnated ribbon gauze was used for nasal packing. Patients with excessive bleeding, significant flap tear and septoplasty performed in combination with other procedures were excluded from the study.

The patients all received routine post-operative care with analgesics (Ibuprofen+ paracetamol) and antibiotics (Ciprofloxacin). Xylomethazoline nasal drop was also used in Group A patients in immediate postoperative period. On the post-operative morning patients were evaluated for pain, nasal obstruction, nasal bleeding and other complications. After discharge patients were reevaluated after 1week and then after 4 weeks.

RESULTS

Total 44 patients underwent septoplasty. Twenty one patients were included in Group A ie. With trans-septal

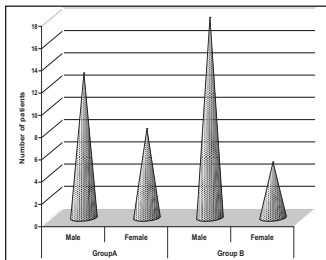


Fig. 1. Sex distribution of the patients

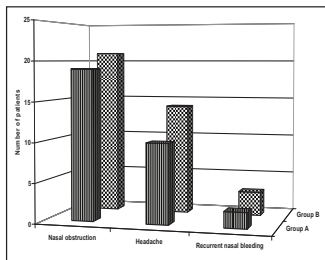


Fig. 2. Symptoms of the patients

suturing and 23 patients were included in Group B i.e with nasal packing. Among 44 patients 31 patients were male and 13 patients were female (Fig.1). Common symptoms were nasal obstruction, headache and recurrent nasal bleeding in these patients (Fig.2). The majority of the patients were between 21 and 30 years of age group (Fig. 3). Pain was assessed with Verbal Rating Scale (VRS)¹ according to which severity of pain was labeled as No pain, Mild pain, Moderate pain, and Severe pain. Eight patients in Group A had no pain at all whereas in Group B every patient had some degree of pain. In Group A, 8 patients had Mild pain, 5 patients had Moderate pain and no patient had Severe pain similarly in Group B, 4 patients had Mild pain, 7 patients had Moderate pain and 12 patients had Severe pain (Fig.4).

On the 1st post operative day all patients had bilateral nasal obstruction in Group B due to nasal packing whereas only 2 patients complained of bilateral nasal obstruction in Group A. Eleven patients in Group A had no nasal obstruction at all (Table-1).

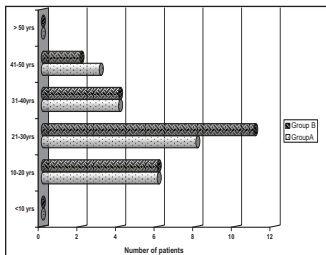


Fig. 3. Age distribution

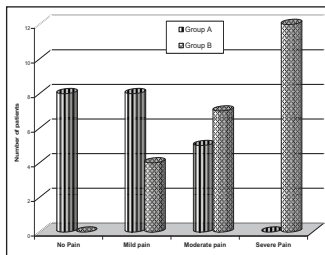


Fig. 4. Postoperative pain (VRS)

Mean hospital stay in Group A was 1.2 days and in Group B was 2.8 days.

In Group A one patient developed epistaxis in 1st post op day which needed anterior nasal packing. In Group A no patient developed synechia and septal perforation during the subsequent follow up. In Group B, 2 patients developed synechia between the lateral wall of nasal cavity and nasal septum. Septal perforation and saddle nose deformity was found in 1-1 patient in Group B.

In subsequent follow up period all patients were satisfied with their surgery except 2 patients in Group A and 3 patients in Group B complained of recurrent nasal blockage. On anterior rhinoscopy post operative septal deviation was not detected in any patient. Recurrent nasal blockage in those patients was explained with associated allergic rhinosinusitis.

DISCUSSION

Nasal packing has been used in septoplasty for many decades to prevent bleeding, hematoma, perforation,

Table-1: Postoperative complications

| Postoperative Complications | | Group | |
|---|------------------------------|---------------------------|-------------------|
| | | A (Trans-septal suturing) | B (Nasal Packing) |
| Obstruction Nasal | No nasal obstruction | 11 | 0 |
| | Unilateral nasal obstruction | 8 | 0 |
| | Bilateral nasal obstruction | 2 | 23 |
| Mean hospital stay | | 1.2 days | 2.8 days |
| Immediate post operative bleeding requiring nasal packing | | 1 | - |
| Synechia between the lateral nasal wall and septum | | 0 | 2 |
| Septal perforation | | 0 | 1 |
| Saddle nose deformity | | 0 | 1 |

and to stabilize the cartilage and bony skeleton. But intranasal packing produces some quality-of-life problems for patients. Major problem is pain during the nasal packing and at the time of removal of packing. Intra nasal packing causes disturbance in endonasal lymph and venous drainage and in nasal respiratory function. This may cause mucosal injury and septal perforation as well as some degree of hypoxia, mouth dryness, sore throat and Eustachian tube dysfunction.²⁻⁴ Serious infections, aspiration and cardiologic complications may also occur.^{5,6} Considering such complications, several studies have been conducted to evaluate the usefulness of nasal packing⁷⁻⁹ Most of these study showed that septoplasty can be safely performed without postoperative nasal packing and some complications can be reduced by non-intranasal pack technique.

In present study post operative pain is significantly low in group A i.e. non-packing group patients. This result is in accordance with the other results.¹⁰⁻¹² Nasal packs contribute significantly to post operative pain especially their removal. Most patients believe that the removal of packs is the most painful event.^{13,14}

In present study only 2 patients of group A had bilateral nasal obstruction in early postoperative days whereas all patients of group B had persistent bilateral nasal obstruction due to nasal packing. Patients with nasal packing have an increased risk of

hypoxaemia, cardiac arrhythmias and mortality.¹⁵ The hypoxia and its consequences have been explained as a result of the nasopulmonary reflex.^{16,17} Nasal obstruction can lead to increased bronchomotor tone leading to increased pulmonary and airway resistance and then to hypoxaemia.¹⁸ The combination of hypoxia and hypercapnia can cause undue stress on the cardiovascular system and lead to myocardial infarction, cerebrovascular accidents and sudden death in susceptible patients.¹⁹ Nasal packing can also cause or worsen sleep-disordered breathing.²⁰

As the intranasal pack was removed after 48 hours and patients were kept in hospital during this period mean hospital stay period was longer in Group B than Group A.

One patient required intranasal packing in Group A for epistaxis in 1st operative day which was removed after 24 hour. This result is similar to Basha *et al* results where 3.2 % of patients required post operative nasal packing.²¹

Post operative complications like synechia development, septal perforation and saddle nose deformity were more common in Group B. It may be due to the mucosal injury and pressure necrosis of nasal septum associated with intranasal packing.

Trans-septal suturing in septoplasty is suggested as a safe procedure that can replace nasal packing, so that

post operative complications especially postoperative pain, discomfort and prolonged hospital stay can be avoided.

REFERENCES

- Amelia W. Pain: a review of three commonly used pain rating scales. *J Clin Nursing* 2005; 14: 798-804
- Ardehali MM, Bastaninejad S. Use of nasal packs and intranasal septal splints following septoplasty. *Int'l J Oral Maxillofac Surg* 2009; 38: 1022-4.
- Jensen PF, Kristensen S, Johannesen NW. Episodic nocturnal hypoxia and nasal packs. *Clin Otolaryngol* 1991; 16: 433-5.
- Thompson AC, Crowther JA. Effect of nasal packing on eustachian tube function. *J Laryngol Otol* 1991; 105: 539-40.
- Huang IT, Podkomorska D, Murphy MN, Hoffer I. Toxic shock syndrome following septoplasty and partial turbinectomy. *J Otolaryngol* 1986; 15: 310-2.
- Yanagisawa E, Latorre R. Choking spells following septorhinoplasty secondary to displaced nasal packing. *Ear Nose Throat J* 1995; 74: 744-6.
- Bajaj Y, Kanatas AN, Carr S, Sethi N, Kelly G. Is nasal packing really required after septoplasty? *Int'l J Clin Pract* 2009; 63: 757-9.
- Marika RD, Steven DP. Postoperative packing after Septoplasty: Is It Necessary? *Otolaryngol Clin N Amer* 2009; 42: 279-85.
- Naghbizadeh B, Peyvandi AA, Naghibzadeh G. Does Post Septoplasty Nasal Packing Reduce Complications? *Acta Medica Iranica* 2011; 49: 9-12.
- Vor-Schoenberg M, Robinson P, Ryan R. Nasal packing after routine nasal surgery. Is it justified? *J laryngol Otol* 1993; 107: 902-5.
- Nunez DA, Martini FW. An evaluation of postoperative packing in nasal septal surgery. *Clin Otolaryngol* 1991; 16: 549-50.
- Weber R, Hochapfel F, Drafi W. Packing and stents in endonasal surgery. *Rhinol* 2000; 38: 49-62.
- Basavaraj N, Walikar S, Rashinkar M, Watwe MV, Fathima A, Kakkeri A. A Comparative Study of Septoplasty With or Without Nasal Packing. *Indian J Otolaryngol Head Neck Surg* 2011; 62: 247-8.
- Samad I, Stevens HE, Maloney A. The efficacy of nasal septal surgery. *J Otolaryngol* 1992; 21: 88-91.
- Jacobs JR, Levine LA, Davis H. Posterior packs and the nasopulmonary reflex. *Laryngoscope* 1981; 91: 279-84.
- Ogura JH, Harvey JE. Nasopulmonary mechanics-experimental evidence of the influence of the upper airway upon the lower. *Acta Otolaryngol* 1971; 71: 123-32.
- Ogura JH, Togawa K, Dammkochler R. Nasal obstruction and the mechanics of breathing physiologic relationships and effects of nasal surgery. *Arch Otolaryngol* 1966; 83: 135-50.
- Cassisi NJ, Biller HF, Ogura JH. Changes in arterial oxygen tension and pulmonary mechanics with the use of posterior packing in epistaxis: a preliminary report. *Laryngoscope* 1971; 85: 2055-68.
- Cook TA, Komron RM. Statistical analysis of the alterations of blood gases produced by nasal packing. *Laryngoscope* 1973; 83: 1802-9.
- Tassan VT, Wynne JW, Cassisi N. The effect of nasal packing on sleep disordered breathing and nocturnal oxygen desaturation. *Laryngoscope* 1981; 91: 1163-71.
- Basha SI, Gupta D, Kaluskar SK. Routine nasal packing following nasal surgery-Is it necessary? *Indian J Otolaryngol Head Neck Surg* 2005; 57: 69-71.